

## Quantitative Electroencephalogram (qEEG) in 14 Year Old Boy With Autism

Utilizing the three dimensional brain imaging by Loreta, a difference of 8.5 standard deviations was observed when comparing digital EEGs performed before and after starting the transdermal reserpine treatment. The red areas designate abnormal brain activity. See Figure 1a and 1b.

Figure 1a. Before starting transdermal reserpine.

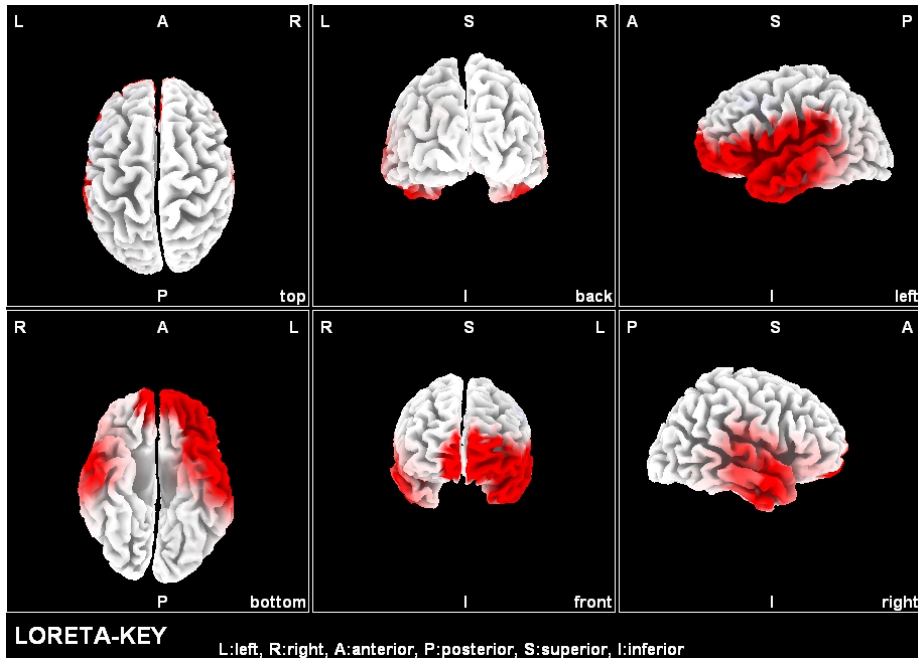


Figure 1b. Three weeks after starting transdermal reserpine.

